

Nocardial Cerebral Abscess Associated with Mycetoma, Pneumonia, and Membranoproliferative Glomerulonephritis[∇]

Ilhan Elmaci,¹ Durmus Senday,² Gökalp Silav,¹ Figen Ekenel,² Naci Balak,^{1*} Erdogan Ayan,¹ Murat Akinci,² Nejat Işık,¹ and Saadet Yazici³

Departments of Neurosurgery,¹ Internal Medicine,² and Clinical Microbiology,³ Göztepe Education and Research Hospital, 34730 Istanbul, Turkey

Received 3 July 2006/Returned for modification 7 November 2006/Accepted 1 April 2007

Nocardial brain abscesses remain a clinical challenge. We successfully treated a patient with nocardial brain abscess, mycetoma, pneumonia, and glomerulonephritis. Nocardial soft tissue involvement, mycetoma, is well known. However, the fact that actinomycetoma can metastasize may not be as well appreciated. The association between nocardiosis and glomerulonephritis should be better clarified.

CASE REPORT

A 49-year-old male, a businessman, was admitted to our hospital with complaints of severe edema of the lower extremities. Clinically, the diagnosis was nephrotic syndrome. Light microscopy of a renal biopsy showed fibrosis with mesangial hypercellularity and tubular atrophy. Immunofluorescence staining revealed deposition of immunoglobulin G and C₃ at the glomeruli, basal membranes, and mesangia. The diagnosis of a membranoproliferative glomerulonephritis was established, and the patient received oral treatment with prednisolone at 60 mg/kg per day. Because of persistent proteinuria, he underwent monthly intravenous pulse cyclophosphamide therapy. When the patient was hospitalized for his third course of cyclophosphamide therapy 9 months later, he was febrile, and physical examination revealed a tender mass in the anterolateral region of the left thigh. Laboratory findings revealed the following: white blood cell count, 13,360/mm³ (normal range, 4 × 10⁹ to 10 × 10⁹/liter); hemoglobin, 10.4 g/dl (normal range, 11 to 16 g/dl); hematocrit, 32.1% (normal range, 37 to 50%); erythrocyte sedimentation rate, 63 mm/h (normal range, <25 mm/h); cyclic AMP receptor protein, 16.2 mg/dl (normal range, <0.8 mg/dl); urea, 35 mg/dl (normal range, 10 to 50 mg/dl); creatinine, 0.8 mg/dl (normal range, 0.7 to 1.2 mg/dl); aspartate aminotransferase, 68 U/liter (normal range, 14 to 36 U/liter); and alanine aminotransferase, 116 U/liter (normal range, 9 to 52 U/liter). There was 5 g/day of proteinuria. Magnetic resonance imaging of the left lower extremity showed a mass lesion within the vastus lateralis muscle (Fig. 1). The mass had cystic characteristics and was multiloculated. The microbiological diagnosis was made from the aspirated pus of the mass lesion in the left lower extremity. The specimens, cultured on sheep blood agar, brain-heart infusion agar, and Sabouraud dextrose agar plates, were incubated at 37°C in the presence of 10% CO₂ plus air. Direct microscopic examination of aspirated Gram-stained pus showed gram-positive cocci,

gram-positive filamentous branching bacilli, and polymorphonuclear neutrophils. The smear was stained with modified acid fast. After a 24-h incubation, typical smooth, yellow-pigmented, hemolyzed colonies were tested with the catalase, oxidase, coagulase, and ID 32 Staph tests (bioMérieux, Nutingen, Germany) and oxacillin on Mueller-Hinton agar. Methicillin-sensitive *Staphylococcus aureus* was identified. After 3 days of incubation, typical dry, chalky, dull, tough colonies appeared on the media. All species were gram-positive branching bacilli. These bacilli were identified as *Nocardia* species. The identification was made by using biochemical and physiological tests which utilize casein, tyrosine, xanthine, hypoxanthine, urease, gelatin, lactose, xylose, and arabinose. The isolates did not utilize casein, tyrosine, xanthine, or hypoxanthine and were urease positive. Gelatin hydrolysis was negative, as was acid production from lactose, xylose, and arabinose. These features identified the causative agent as the *Nocardia asteroides* complex. An antibiotic sensitivity test performed on Mueller-Hinton agar using the disk diffusion method showed that there was sensitivity to co-trimoxazole, cefotaxime, and tobramycin after 72 h. Although the CLSI (formerly NCCLS) advises agar dilution tests for nocardiae, the agar dilution test could not be performed in our laboratory at that time (13). Instead, the disk susceptibility test was done using susceptibility breakpoints for gram-positive bacilli. The specific species, however, could not be identified with routine laboratory examination.

The patient was diagnosed as having a mycetoma, and antibiotic therapy was started with orally administered trimethoprim-sulfamethoxazole (TMP/SMX) and intravenously administered cephazoline. The following day, the patient had a seizure and developed amnesia. Cranial magnetic resonance imaging studies were consistent with abscess formation in the left temporo-occipital region (Fig. 2). Because of suspicion of multisystem nocardiosis, the patient underwent computed tomography scanning of the thorax. It revealed areas of consolidation and atelectasia in the basal segments of the left lung and centrally necrotizing lymphadenopathy in the left para-aortic region. Since there was no adequate response to medical therapy with TMP/SMX for 2 months, the patient underwent a left temporo-occipital craniotomy and the abscess was excised

* Corresponding author. Mailing address: Göztepe Eğitim ve Araştırma Hastanesi, Nöroşirürji Kliniği, Kadıköy, Istanbul 34730, Turkey. Phone: 90 (216) 566 6262. Fax: 90 (216) 372 8780. E-mail: naci.balak@atglobal.net or drnacibalak@yahoo.com.

[∇] Published ahead of print on 11 April 2007.

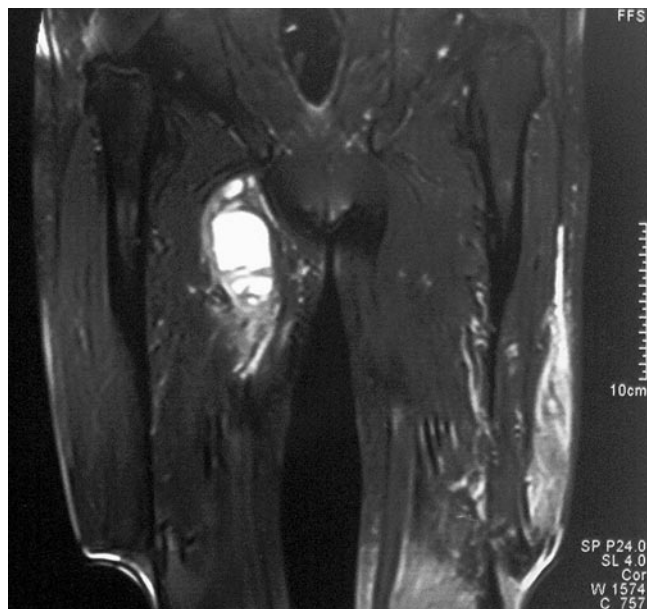


FIG. 1. Magnetic resonance image of the left lower extremity showing a multiloculated cystic mass, measuring about 10 by 3 cm.

with its capsule (Fig. 3). Using the same isolation methods as those mentioned above (including the smears), the *Nocardia asteroides* complex was again identified in cultures of the drainage specimen obtained from the cerebral abscess excised on 26 July 2004. After the surgery, the patient recovered progressively. At the fourth month after the surgery, medical therapy with TMP/SMX continued with a dose of 10 mg/kg trimethoprim per day, and the patient had no complaints. Lab-

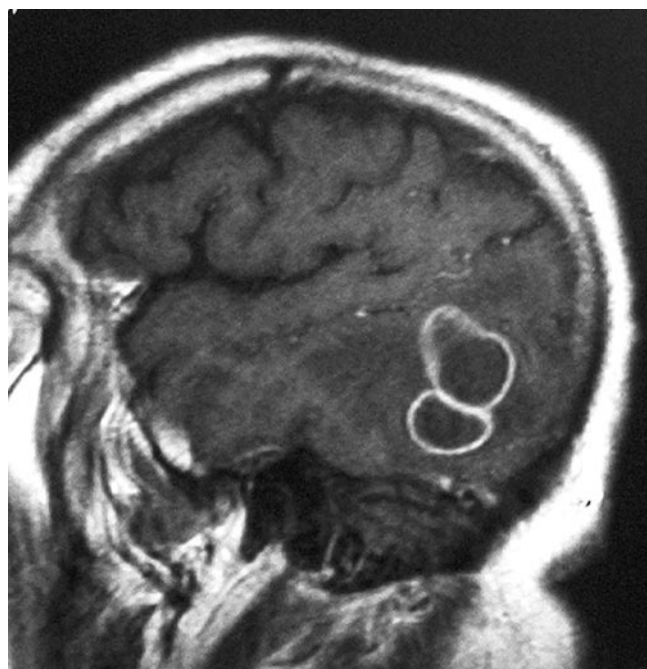

FIG. 2. Cranial sagittal T1-weighted magnetic resonance image showing an abscess formation in the left temporo-occipital region.

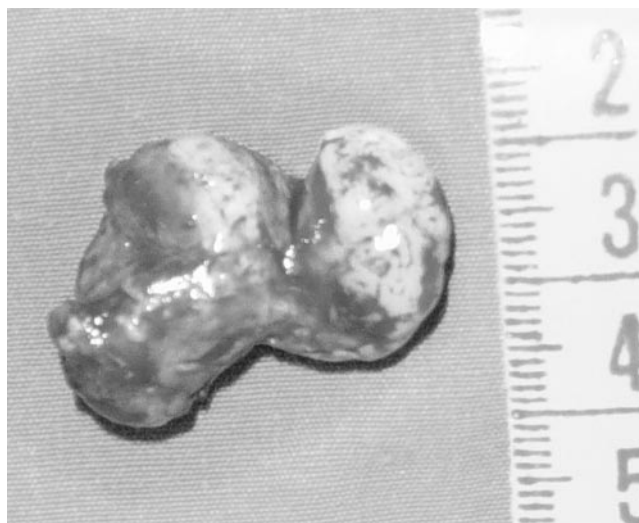


FIG. 3. Cerebral abscess mass after complete removal.

oratory findings remained normal. Postoperative cranial magnetic resonance images showed no abscess in the brain.

Discussion. Nocardiae are gram-positive, aerobic actinomycetes found naturally in the soil, air, and sewage (1, 12). Members of the *Nocardia asteroides* complex account for 80% of cases of noncutaneous invasive nocardiosis and most systemic or central nervous system nocardiosis (7). Nocardial brain abscesses remain a clinical challenge associated with high mortality and morbidity rates (2, 7, 10, 12, 14).

The patient was a businessman, and hence inoculation of the nocardia could not be directly related to his occupation. It is generally accepted that the primary infection by nocardiae is most commonly acquired via the respiratory tract (7). Primary pulmonary lesions may be subclinical or overt, chronic, or, rarely, acute (3). *Nocardia asteroides* may cause mycetomas. Mycetoma is a chronic granulomatous process resulting from the implantation of one of various fungi or actinomycetes into soft tissues, usually of the foot (8, 11). The disease is almost painless, and there are few or no constitutional symptoms unless there is a secondary bacterial infection (8). The microbial colonies form grains and sinuses in soft tissues. A literature survey revealed that the flora causing mycetoma in Turkey consists of various pathogens, such as *Nocardia asteroides*, *Nocardia brasiliensis*, *Scedosporium apiospermum*, *Aspergillus niger*, and *Streptomyces madurae* (4).

Nocardiosis is an opportunistic infection that has been noted in patients with malignancies, systemic lupus erythematosus, or HIV infection and in long-term steroid users and transplant recipients (2, 6, 9). However, recent data demonstrate that central nervous system nocardiosis is as common or more prevalent in patients with normal immune systems (12). Therefore, the nocardiae may have a predilection for some, but not all, immunocompromised patients. For example, most transplant patients reported to have nocardiosis are renal-transplant recipients. In 1998, Jose et al. reported an association between mesangiocapillary glomerulonephritis and nocardiosis (5).

There are similarities between our patient and their patient. There were no primary immune deficiency disorders in either case. Both patients had glomerulonephritis and received corticosteroids, although the patient in the case report of Jose et al. received up to 100 mg daily of prednisolone for 6 years because of cluster headaches, not for glomerulonephritis. In our case, it is unclear whether there was a predisposition to nocardia infection directly linked to the glomerulonephritis or if it was a secondary consequence of prolonged immunosuppression due to treatment with prednisolone (60 mg daily) and cyclophosphamide for 9 months. This therapy could have aggravated a silent chronic infection in the soft tissue of the leg, a mycetoma by *Nocardia asteroides*. In the literature, the average duration of the symptoms in mycetomas has been calculated as 8 years (8). However, in our case, lesions in the lungs and in the brain were revealed in the relatively short time period after the symptoms of mycetoma appeared. Also, Jose et al. made the diagnoses of glomerulonephritis and nocardiosis in their case nearly simultaneously. Therefore, there may be a link between glomerulonephritis and nocardiosis, since the diagnoses of these clinical entities could be made sequentially in a relatively short time in both cases.

In our case, the surgical excision of the nocardial brain abscess was successful. In 2002, Lee et al. recommended that nocardial cerebral abscesses be initially treated via aspiration, with aggressive surgical management being reserved for the small proportion of patients who do not respond to minimally invasive surgery (7). However, only one patient in their series was discharged in good condition after a single aspiration procedure. In their other patients, more than one aspiration or excision of the abscess was necessary to achieve a positive outcome. These findings support those of Mamelak et al., who reviewed the medical literature in 1994 and stated that the mortality rate (24%) among patients undergoing craniotomy and excision was less than half that (50%) among patients undergoing aspiration and drainage alone (10).

Mycetomas may be confused with granulomas, abscesses, or benign soft-tissue tumors, and this may result in delayed diagnosis of a possible nocardial infection. It is well understood that nocardial mycetoma may lead to new lesions in vital or-

gans, such as the lungs and brain. However, the fact that actinomycetoma can metastasize may not be as well appreciated. Additionally, the relationship between nocardiosis and glomerulonephritis should not be regarded solely as an effect of immunosuppression but should also be clarified in terms of specific pathophysiological mechanisms. Surgical excision of nocardial cerebral abscesses instead of an aspiration procedure may be more beneficial in some patients.

We thank Erin Houlihan for her editorial assistance.

REFERENCES

1. Agarwal, R., A. Ayyagary, K. N. Prasad, V. L. Nag, and R. K. Sharma. 1999. Mycopathologia 148:113–115.
2. Barnaud, G., C. Deschamps, V. Manceron, E. Mortier, F. Laurent, F. Bert, P. Boiron, P. Vinceneux, and C. Brangler. 2005. Brain abscess caused by *Nocardia cyriacigeorgica* in a patient with human immunodeficiency virus infection. *J. Clin. Microbiol.* 43:4895–4897.
3. Boiron, P., F. Provost, G. Chevrier, and B. Dupont. 1992. Review of nocardial infections in France 1987 to 1990. *Eur. J. Clin. Microbiol. Infect. Dis.* 11:709–714.
4. Erbakan, N., A. N. Or, M. Ünal, and Z. Palali. 1973. A review of mycetomas in Turkey. *Mycopathol. Mycol. Appl.* 51:105–113.
5. Jose, M. D., K. M. Bannister, A. R. Clarkson, F. J. Whitehead, and R. J. Faul. 1998. Mesangiocapillary glomerulonephritis in a patient with nocardia pneumonia. 1998. *Nephrol. Dial. Transplant* 13:2628–2629.
6. Kayacan, S. M., A. Türkmen, H. Alis, M. Imer, O. Barlas, S. T. Eder, A. Yildiz, A. E. Aydin, U. Eldegez, and M. S. Sever. 2001. Successful therapy combined with surgery for severe post-transplant nocardiosis. *J. Nephrol.* 14:304–306.
7. Lee, G. Y. F., R. T. Daniel, B. P. Brophy, and P. L. Reilly. 2002. Surgical treatment of nocardial brain abscesses. *Neurosurgery* 51:668–672.
8. Lewall, D. B., S. Ofole, and B. Bendl. 1985. Mycetoma. *Skeletal Radiol.* 14:257–262.
9. Magee, C. C., R. D. Halligan, E. L. Millford, and M. H. Sayegh. 1999. Nocardial infection in a renal transplant recipient on tacrolimus and mycophenolate mofetil. *Clin. Nephrol.* 52:44–46.
10. Mamelak, A. N., W. G. Obana, J. F. P. Flaherty, F. P. John, and M. L. Rosenblum. 1994. Nocardial brain abscess: treatment strategies and factors influencing outcome. *Neurosurgery* 35:622–631.
11. Middendorp, U. G. 1968. Der Madurafuß oder das Mycetom. *Arch. Ortho. Unfall-Chir.* 64:328–363.
12. Mogilner, A., G. Jallo, D. Zagzag, and P. Kelly. 1998. Nocardia abscess of the chroid plexus: clinical and pathological case report. *Neurosurgery* 43:949–952.
13. NCCLS. 2003. Susceptibility testing of mycobacteria, nocardiae, and other aerobic actinomycetes. Approved standard. NCCLS document M 24-A. National Committee for Clinical Laboratory Standards, Wayne, Pa.
14. Talwar, P., A. Chakrabarti, A. Ayyagari, N. Nayak, V. K. Khosla, M. Minz, and R. V. S. Yadav. 1989. Brain abscess due to nocardia. *Mycopathologia* 108:21–23.